

CLINICAL REVIEW

Corneal Transplantation: Dental Lamina as Keratoprosthesis

Sourabh Arora, BSc
Taha Bandukwala, BSc

ABSTRACT

Corneal diseases are among the major causes of global blindness, second only to cataracts in overall significance. The etiology of corneal blindness includes various infectious and inflammatory eye diseases that cause corneal scarring, which ultimately leads to functional blindness. Anatomically, the cornea is the outermost layer of the eye and is primarily responsible for light refraction, allowing for central and peripheral vision. In cases where less invasive treatments for corneal disease fail, corneal transplant is indicated, which has the highest success rate of any transplant procedure. The simplest form of corneal transplant, Penetrating Keratoplasty (PKP), is performed by transplanting a donor cornea from a cadaver. The authors review a more complex form of corneal transplant, Osteo-Odonto Keratoprosthesis (OOKP), which is a two-stage procedure wherein dental and buccal tissue is auto-transplanted to replace the cornea. This review comprises relevant anatomy, the procedure, surgical interprofessionalism, indications, contraindications, complications, patient outcomes and future scope of OOKP.

INTRODUCTION

According to the World Health Organization, in 2001 more than 135 million individuals had severely impaired vision in both eyes, with hundreds of millions experiencing monocular vision loss.¹ In recent years, the etiology of blindness has shifted from traditional infectious causes, such as trachoma and leprosy, to other causes such as cataract or corneal dysfunction. Ocular disease affecting the cornea presents in a wide variety of infectious and inflammatory conditions. In addition, the prevalence of corneal blindness varies from one population to another, depending on many factors such as availability and general standards of eye care.

Corneal transplantation, referred to as Penetrating Keratoplasty (PKP), is a procedure performed by ophthalmologists to treat severe visual impairment or pain, for cases in which the outermost transparent covering of the eyes (the cornea, see Figure 1) cannot be treated by non-invasive means. PKP involves replacing the cornea with donor cadaveric corneal tissue, and according to the Canadian National Institute for the Blind, its 85% success rate is the highest of all tissue transplantations.² When a PKP is unsuccessful, Keratoprosthesis is recommended, wherein a non-donor,

synthetic cornea is grafted. For over 200 years, a variety of prosthetic corneas made of materials such as champagne corks and hydroxyapatite have been implanted in place of cadaveric tissue.³ The ideal keratoprosthesis would improve optical quality, have a specifiable power, be accepted by the patient's immune system, allow for ocular examination and last the patient's lifetime. While none of the synthetic corneas used thus far show all these traits, the use of dental lamina tissue has become the most common form of Keratoprosthesis.³

As of September 2009, the United States joined Italy, Japan, Singapore and other nations in being host to the modified Osteo-Odonto Keratoprosthesis (OOKP).⁴ This procedure, performed in 2009 at Miami's Bascom Palmer Eye Institute, is yet to be reviewed in scientific literature. However, OOKP is a highly cited topic because it is an example of interdisciplinary patient care in which eye specialists, dental surgeons, anaesthesiologists, and other medical professionals collaborate on a multi-stage procedure. Strampelli fashioned the procedure in the early 1960s, and to date nearly 600 surgeries have been attempted.³ OOKP is a last-resort treatment for ocular problems rooted in corneal dysfunction and recipients are required to meet stringent criteria.

OCULAR ANATOMY

With adequate light, the visual system allows images to be viewed and constructed for interpretation. Light waves reflect from objects and the cornea is the first surface through which they travel, as they head through the pupil toward the lens. Approximately 75% of the refraction (bending of light waves) is attributed to the cornea, which is an essential part of focusing images to a specific point on the retina.⁵ When the image is correctly projected onto the retina at the posterior of the eye, neural tissue transmits the information to the brain.

Structurally, the cornea is a 550 μm -thick transparent tissue overlying the pupil and iris, serving as the outer covering of the anterior chamber. It is a dome-shaped, avascular structure composed of five layers: the epithelial layer is most superficial, followed by Bowman's membrane, stroma, Descemet's membrane and endothelium.⁶ Changes in the shape, consistency, or composition of the cornea from tissue injury or disease have significant effect on visual acuity.

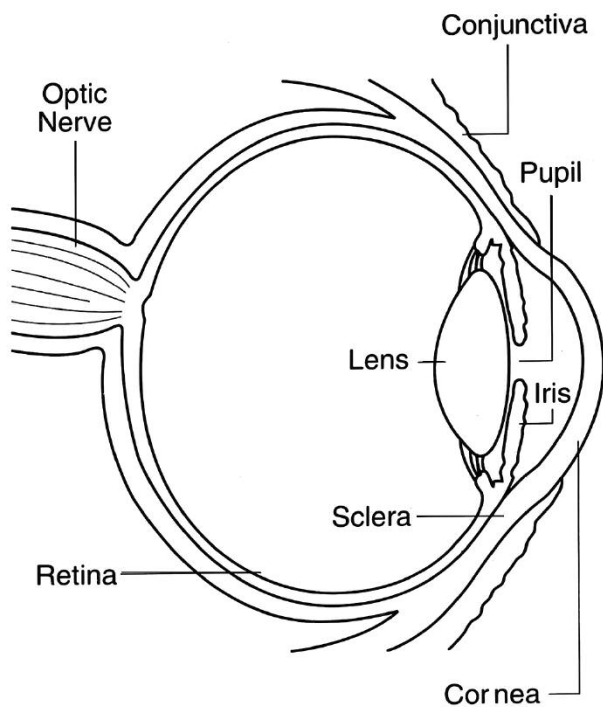


Figure 1. Schematic of the eye. Image reproduced from National Eye Institute, <http://www.nei.nih.gov/>.

INDICATIONS AND CONTRAINDICATIONS

Strampelli described the original OOKP forty years ago after using a patient's own tooth root and alveolar bone to create an optical cylinder.⁷ Efforts to follow this procedure were unsuccessful until Falcinelli refined and reintroduced it to Britain in the mid-1990s.^{8,9} The modern or Falcinelli OOKP was recommended for patients with a history of

failed PKPs due to graft-versus-host immune-mediated rejection, or for those suffering from bilateral corneal blindness secondary to corneal diseases that impair normal refraction. Some of these conditions include Stevens-Johnson syndrome (a hypersensitivity autoimmune reaction against certain drugs and infections leading to corneal scarring), chemical burns, trachoma (Chlamydial infection), and refractory dry eyes. Indications for OOKP beyond the initial insults to the cornea include the ability to count fingers, and to perceive hand motion and light. Contraindications include a lack of teeth, being under the age of 17, advanced glaucoma, or irreparable retinal detachment.³ Pre-operative assessment is completed by an ophthalmologist who assesses whether the retina and optic nerve are normal and functioning, and by a maxilla-facial surgeon who completes an oral examination to decide which tooth (typically a canine) is most appropriate for implantation, and to assess the health of the buccal membranes (tissue from inside the cheek).

OSTEO-ODONTO KERATOPROSTHESIS: THE PROCEDURE

The procedure is typically completed in two stages separated by two to four months, as described in *Seminars in Ophthalmology* in 2005.³ During the first stage, a canine tooth is extracted with the entire root (Figure 2) and a portion of the jaw bone. The top part of the tooth (the crown) is removed and the remaining root, bone and tissue are shaped into a cube, referred to as the dental lamina. A hole is drilled in the centre of the dental lamina and a small, transparent, plastic optical cylinder is fitted into the hole and sealed with dental cement. This optical cylinder acts as the media for light to travel through and focus on the retina. The dental lamina is inserted through a slit below the lower eyelid of the affected eye.

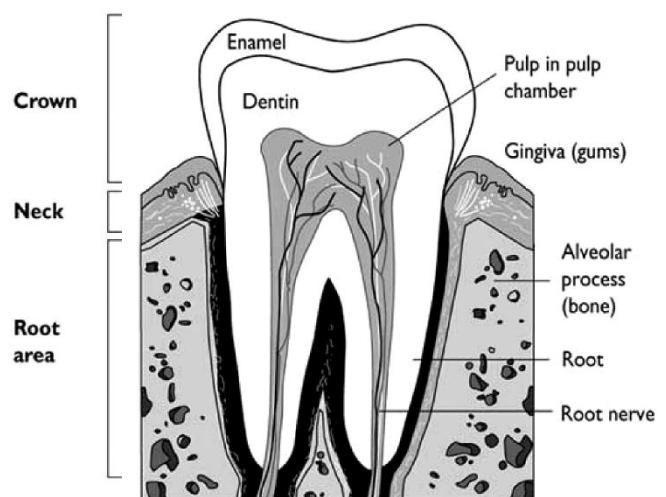


Figure 2. Schematic of the tooth. Image reproduced from Studio Dentaire, www.studiodentaire.com/en/glossary/cusp.php.

The last step of stage one involves superficial keratectomy (removal of the superficial layer of the cornea) and replacement with a piece of buccal mucous membrane, which is sutured to the sclera (outer layer of the eye, adjacent to cornea) thus creating a new ocular surface. Then follows a two to four month interim period, which allows the dental lamina to heal and become vascularized.

Stage two involves moving the dental lamina and the tissue which has grown over the optical cylinder, from underneath the eyelid to the centre of the eye. The buccal mucous graft tissue is lifted, and a hole is created in the center of the patient's remaining original cornea wide enough to fit the optical cylinder. The iris is then removed (iridodialysis), the lens extracted, and an anterior vitrectomy (removal of vitreous, the gel-like fluid which supports the eye) is performed to create space for the new implanting tissues. The dental lamina, including the optical cylinder, is then inserted through the corneal hole and put into position by sutures to the host cornea and sclera. The eye is then re-inflated with filtered air. The final step involves creating a hole in the buccal mucous graft tissue wide enough to allow light to enter the optical cylinder and then suturing the buccal graft back onto the sclera (Figure 3). The patient should be able to see within two weeks. Immediate post-operative care includes medications for symptom relief like prednisolone (corticosteroid), and antibiotic prophylaxis. Patients require lifetime follow-up with an ophthalmologist.

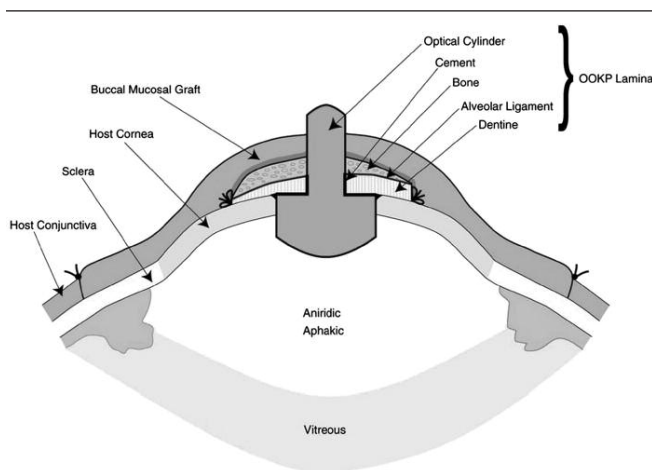


Figure 3. Schematic of completed OOKP. Image reproduced from Stanford Wellsphere, <http://stanford.wellsphere.com/dental-health-article/using-a-tooth-to-help-the-blind/788589>, courtesy of Dr. Dean Brandon.

RESULTS

Falcinelli reported impressive results, as 75% of his OOKP patients were able to see 20/40 or better and 85% had anatomical stability (n=181).⁸ In a study by Hille et al., of eight patients who underwent OOKP, four had a best visual acuity of 0.6 to 0.9 (20/33 to 20/22) and all eight patients had stable prosthesis.¹⁰ Other studies have shown similar results, wherein outcomes of OOKP are superior to most methods for managing end-stage corneal diseases.^{9,11}

DISCUSSION

In reviewing the efficacy of OOKP procedures, the complications are a significant consideration. Complications of OOKP are on a wide spectrum, with possible oral, ocular or systemic involvement if the patient is immunocompromised. Vitreous hemorrhaging (bleeding within the eye) and retinal detachment are serious adverse outcomes that can occur after stage two. Movement of the optical cylinder is a complication which would require additional surgery to fix it in place. The ocular or buccal membranes are at risk for infection at all stages, and prompt attention to these areas should be given if there are any signs of pain or inflammation. Glaucoma is a major associated problem and its incidence has been cited in up to 75% of OOKP patients.³ One reason for the high incidence of glaucoma is that neither intraocular pressures nor visual field testing can be accurately measured in the OOKP eye. Consequently, diagnosis depends upon less exact methods, such as the patient's subjective visual field defects.

Although the complications of OOKP can vary in severity, the majority of patients have stable implants. Because OOKP has been shown to improve and maintain visual acuity, this procedure is an innovative alternative for managing end-stage ocular surface diseases after failed PKPs. The procedure remains technically difficult, and requires special training by the health care professionals and healthy dentine and buccal tissues in the patient. Current research focuses on creating synthetic analogues to substitute the dental lamina and as well as accurately measuring intraocular pressures to assess for glaucoma in post-transplant patients.

The future of OOKP is promising, as the literature and scientific interest is increasing. Modern OOKP surgery still has many barriers to becoming universally accepted including the required technical and surgical expertise, but it provides hope for restoring vision in refractory corneal blindness. The creativity of using a tooth as an eye implant should inspire future interprofessional approaches to ophthalmic practice in order to provide the best care for patients. †

REFERENCES

- Whitcher JP, Srinivasan M, Upadhyay MP. Corneal blindness: A global perspective. *Bull World Health Org* 2001; 79: 214-21.
- Canadian National Institute for the Blind. (2009). Gift of sight: Corneal transplants. Retrieved September 28, 2009, from the World Wide Web: <http://www.cnib.ca/en/support/gift-sight/Default.aspx>.
- Liu C, Paul B, Tandon R, et al. The Osteo-Odonto-Keratoprosthesis (OOKP). *Seminars in Ophthalmology* 2005; 20: 113-28.
- CBN News. (2009). Tooth-to-eye transplant saves vision. Retrieved September 27, 2009, from the World Wide Web: <http://www.cbn.com/cbnnews/health-science/2009/September/Tooth-to-Eye-Transplant-Saves-Vision/>.
- Goldstein EB. *Sensation & Perception*. 7th ed. Canada: Thompson Wadsworth, 2007.
- Snell RS & Lemp MA (eds). *Clinical Anatomy of the Eye*. England: Blackwell Services Inc; 1998.
- Strampelli, B. Keratoprosthesis with osteodontal tissue. *Am J Ophthalmol* 1963; 89: 1029-39.
- Falcinelli G, Barogi G, Taloni M. Osteodontokeratoprosthesis: Present experience and future prospects. *Refract Corneal Surg* 1993; 9: 193-94.
- Falcinelli G, Barogi G, Caselli M, et al. Personal changes and innovations in Strampelli's osteo-odonto-keratoprosthesis. *An Inst Barraquet* 1999; 29: 47-48.
- Hille K, Landau H, Ruprecht KW. Osteo-odonto-keratoprosthesis: A summary of 6 years surgical experience. *Ophthalmologie* 2002; 99: 90-95.
- Tay AB, Tan DT, Lye KW, et al. Osteo-odonto-keratoprosthesis surgery: A combined ocular-oral procedure for ocular blindness. *Int J Oral Maxillofacial Surg* 2007; 36: 807-13.

Author Biographies

Sourabh Arora is a first-year student at the Michael G. DeGroote School of Medicine, McMaster University. He is a resident of Richmond Hill, Ontario who completed a three-year Bachelor of Science (Major in the Medical Sciences) at the University of Western Ontario.

Taha Bandukwala is a second-year student at the Michael G. DeGroote School of Medicine, McMaster University. He is a resident of Markham, Ontario who completed a three-year Bachelor of Science (Major in the Medical Sciences) at the University of Western Ontario.

Find the money to grow throughout your professional career.

Scotia Professional[®] Plan is a flexible and comprehensive financial solution that integrates your business and personal financial needs into one customized package. Whether you're a student, a professional operating your own practice, an associate or salaried professional, *Scotia Professional* Plan is designed to fit your unique financial needs.

To learn more, speak to your Scotiabank Professional Banker today.

Annetta Westenek
Manager, Small Business
& Professional Banking

Scotia Professional Plan

University Plaza
24 Plaza Drive
Dundas, ON
905-627-9146



© Registered trademarks of The Bank of Nova Scotia.



JOSEPH BRANT
MEMORIAL HOSPITAL

For more than 40 years, Joseph Brant Memorial Hospital has earned an enviable reputation as a full service, patient-focused community hospital serving Burlington and the surrounding area. We're committed to providing excellence in health care to our community. Join us in a city that offers an exceptional lifestyle and a variety of amenities just 40 minutes west of Toronto.

The Hospital and the Burlington community have been designated as under serviced by the MOH & LTC for **Family Physicians.**

If you are interested in exploring any opportunities, please contact:

Dr. R. Cross
Chief of Staff
Joseph Brant Memorial Hospital
1230 North Shore Boulevard
Burlington, Ontario
L7R 4C4

Phone: (905) 681-4812
Fax: (905) 336-6480
E-mail: awoodall@jbmh.com

www.jbmh.com