

BRIEF CASE

Gastric Carcinoma: An Unexpected Diagnosis

Dr. Catherine Hanley, BSc(OT), MD

THE CASE

Mr. S is a 66-year-old man who recently presented to his family doctor with a one month history of epigastric pain and nausea. His pain was persistent, dull and increased with eating. He had never experienced this pain before. He had also had a few months' history of weight loss and noticed a decreased abdominal girth, with his clothes fitting more loosely. He denied any dysphagia, changes in bowel movements, melena or hematochezia. He did not have a history of peptic ulcer disease or gastroesophageal reflux disease (GERD). His past medical history included coronary artery disease with a myocardial infarction in 1993, and a coronary artery bypass graft (CABG) six years prior. He had a 30-pack-year history of smoking, but had quit smoking ten years ago. He had also had a chronically low vitamin B₁₂ level and received monthly injections. His current medications include metoprolol, atorvastatin and aspirin. He is married and has six children. He drinks alcohol only on special occasions.

What is the Differential Diagnosis from the Patient's History?

Epigastric pain and nausea are non-specific symptoms that can generate a broad differential diagnosis. These diagnoses range from those that are benign and can be treated conservatively, to those that are malignant and require more aggressive intervention. The differential diagnosis at this time for Mr. S includes peptic ulcer disease, biliary colic, pancreatitis, gastroesophageal reflux disease (GERD), gastritis and upper GI malignancy. A common diagnosis to consider in a patient with these symptoms is peptic ulcer disease. Of particular note, food intake exacerbated Mr. S's symptoms, a finding which is characteristic of a gastric ulcer, whereas patients with duodenal ulcer disease often find that food relieves their symptoms.¹ Anemia, melena and positive fecal occult blood samples may be present in peptic ulcer disease, whereas weight loss is not usually associated with it. The most common etiologies for ulcers are typically the bacterium *Helicobacter pylori* or non-steroidal anti-inflammatory medications (NSAIDs).² To make a diagnosis of *H. pylori*, a blood test and upper gastrointestinal endoscopy with biopsies must be done.

Biliary colic is the most common symptomatic presentation of gallbladder disease. Patients who present with biliary colic

often have episodes of postprandial pain (especially following fatty meals), and their pain usually begins abruptly and subsides gradually after a few minutes to several hours.¹ Nausea and vomiting can occur during attacks of biliary colic, but not usually between attacks. Weight loss and anorexia are not common symptoms. Pain is episodic and usually localized to the right upper quadrant, but can be felt across the epigastrium and through to the back, or referred to the area overlying the scapulae. Liver enzymes, as well as leukocyte counts, are usually normal in patients with biliary colic. An ultrasound is the gold standard diagnostic test for cholelithiasis, with both a specificity and sensitivity of 95%.¹

Pancreatitis is also on the differential diagnosis for Mr. S. In acute pancreatitis, signs and symptoms may include a very tender epigastrium with guarding, fever, nausea and profuse vomiting. Bloodwork often demonstrates a moderate leukocytosis, (usually not higher than 12,000/UL) as well as elevated amylase and lipase levels.¹ In the case of chronic pancreatitis, one would expect Mr. S to be experiencing intermittent epigastric pain, as well as weight loss due to malabsorption.³ Further, abdominal ultrasound would potentially show pancreatic abnormalities. That being said, CT remains the best method to rule out chronic pancreatitis, as it has the greatest sensitivity for showing gland enlargement, atrophy, inflammation or calcification.³ Gallstones represent the most common etiology of pancreatitis, accounting for 60% of all cases. Alcohol consumption accounts for most of the remaining 40%.³

Gastroesophageal reflux or gastritis are certainly other diagnostic possibilities for Mr. S's presentation. The pain of reflux is of a burning nature, can be worse at night and is exacerbated by irritants such as alcohol, aspirin and caffeine.³ Gastritis can also cause epigastric pain, and can be associated with these same caustic agents. GERD and gastritis can both cause nausea and vomiting in patients, but is not usually accompanied by weight loss. Both are best diagnosed by endoscopy, and often an improvement in symptoms with empirical treatment (H₂ blockers or proton pump inhibitors), as well as lifestyle changes, can help to confirm the diagnosis.³

Considering an upper GI malignancy in the differential diagnosis – specifically an esophageal malignancy – one would typically observe the presence of varying degrees of dysphagia in these neoplasms. Gastric malignancy, on the other hand, often

presents with insidious upper abdominal discomfort, as well as nausea and weight loss (see Table 1).³ Other clues pointing to a gastric malignancy include anemia or positive fecal occult stool samples. Though a double contrast upper gastrointestinal series is 95% sensitive for diagnosing gastric carcinoma, endoscopy with biopsy remains the most sensitive method of establishing this diagnosis.^{3,4} Pancreatic malignancy is also included on the list of differential diagnoses for Mr. S, though patients usually present with pain, weight loss and jaundice. The best initial diagnostic test for pancreatic malignancy is a CT scan.³

Table 1. Presenting Symptoms of Gastric Cancer

Weight loss	62%
Abdominal Pain	52%
Nausea	34%
Dysphagia	26%
Melena	20%
Early Satiety	18%
Ulcer-type pain	17%

Printed with permission from UpToDate, Inc. Schroy, PC. Clinical Features and diagnosis of gastric cancer. In: UpToDate, Rose, BD (Ed), UpToDate, Inc. Wellesley, MA 2003. For more information visit www.uptodate.com.

THE CASE

On examination, the patient appeared pale and there was some mild epigastric tenderness. No masses were palpated, and no peritoneal signs, such as acute generalized abdominal pain, rebound tenderness or guarding, were present. At this time, the family physician did bloodwork, specifically looking for *Helicobacter pylori*, while starting Mr. S empirically on triple therapy for *H. pylori* eradication (omeprazole, clarithromycin, metronidazole). He was then referred to a gastroenterologist for endoscopy.

When Mr. S's bloodwork came back, it revealed the presence of *H. pylori* antibodies at a level of 50.9 U/mL (normal ≤ 15 U/mL). However, there were no signs of anemia (hemoglobin 148g/L), and all other bloodwork, including liver enzymes, was normal. Serum amylase and lipase, as well as fecal occult blood testing were not done. An abdominal ultrasound showed no cholelithiasis or other abnormalities.

How Significant is *H. pylori*?

Studies have shown a consistent association between *Helicobacter pylori* and risk of gastric cancer.^{1,6} Those with *H. pylori* infection have a 3.6 to 18-fold higher risk of gastric carcinoma of the body or antrum of the stomach than those without infection. This association is seen largely with intestinal-type cancers and seems to be proportional to the serum levels of *H. pylori* antibodies. Although the exact role of *H. pylori* in gastric carcinogenesis is unclear, it is associated with the development of chronic atrophic gastritis – a known precursor to gastric carcinoma (see Table 3).^{2,6}

THE CASE

One month later, Mr. S again presented to his family physician with unremitting epigastric pain, unrelieved by a completed course of triple therapy. His endoscopy had been booked and was one week away. The next evening, Mr. S arrived at the emergency department with a one-hour history of hematemesis. He had been out for a late lunch and had started vomiting once he arrived home. He was fully conscious and alert on arrival to ER, though he was tachycardic at 115 beats per minute, and hypotensive at a blood pressure of 75/35 mmHg. He was urgently referred to surgery and sent to the ICU for stabilization. Mr. S was subsequently intubated and a nasogastric (NG) tube was inserted. He had vomited approximately 1.5L of bright red blood in the ER, and 2.5 L in the ICU, preempting any endoscopic investigation and indicating a need for emergent laparotomy. In the OR, after vigorous attempts at stabilization, a midline laparotomy revealed a stomach grossly distended with blood. The NG tube continued to drain large

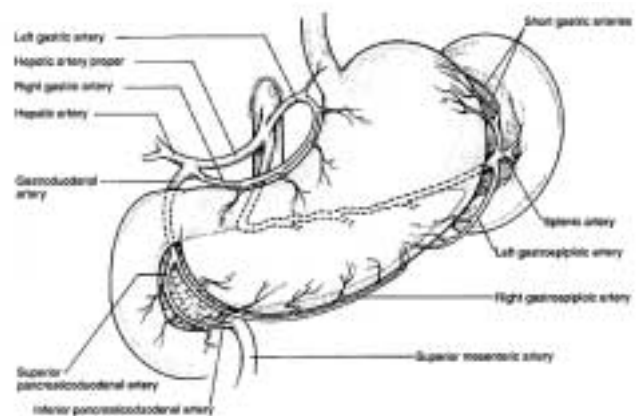


Figure 1. Anatomy of the stomach and splenic artery

Lawrence, P. Essentials of General Surgery, Third Edition. Lippincott Williams & Wilkins, 2000.

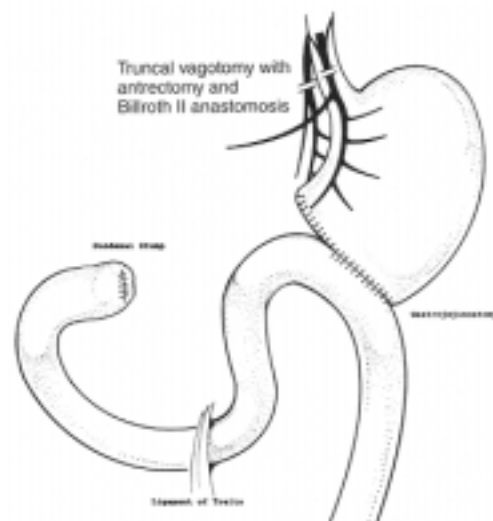


Figure 2. Gastrectomy

Lawrence, P. Essentials of General Surgery, Third Edition. Lippincott Williams & Wilkins, 2000.

amounts of blood. When an anterior gastrotomy was performed, a very large ulcer crater (greater than 10cm in diameter) was present on the posterior wall and had eroded through the stomach wall, into the splenic artery and pancreas (Figure 1). A partial gastrectomy and gastrojejunostomy were performed with clips being applied to both ends of the splenic artery lying in the bed of the ulcer (Figure 2). The ulcer bed included the pancreas, and the stomach had to be resected around the ulcer bed. During surgery, the splenic artery continued to bleed, sending Mr. S into hypovolemic shock, with a hemoglobin down to 30g/L and a platelet count of $3 \times 10^9/L$. During the surgery, Mr. S arrested. He was given fresh frozen plasma and over 10 units of blood. Mr. S left the operating room three hours later in stable condition with a systolic blood pressure of 80mmHg.

Why Did He Bleed?

The differential diagnosis for upper gastrointestinal hemorrhage includes peptic ulcers, esophageal varices, gastritis and Mallory-Weiss syndrome. Uncommon causes include gastric carcinoma, pancreatitis and esophagitis.¹ According to the Classification of Hemorrhagic Shock,³ Mr. S experienced a Class 4 hemorrhage, meaning greater than 40% (or 2000mL) of blood volume lost. He also developed a coagulopathy as his INR (which had been normal prior to surgery at 1.2) climbed to 4.3. This was likely due to massive blood loss (and thus platelet loss) as well as the dilution of clotting factors from his multiple red blood transfusions.³ In addition, shock can either cause or aggravate disseminated intravascular coagulation (DIC). Hypotension that leads to stasis can prevent normal circulating inhibitors of coagulation from reaching sites of microthrombi and DIC can be the result.³ With severe DIC, replacement of coagulation factors is accomplished through cryoprecipitate or fresh frozen plasma. Platelet transfusions can also be required as they were in the case of Mr. S.³

THE CASE

Mr. S remained in the ICU for eight days postoperatively. His hemoglobin stabilized at 80g/L, and there was no further evidence of active bleeding. A gastrograffin study post-operatively demonstrated that much of the gastrograffin refluxed into Mr. S's esophagus and did not pass into the efferent loop of his anastomosis. Upper endoscopy showed necrosis of the distal remnant of the stomach and biopsies were taken at the site of the anastomosis (Figure 3). The afferent loop of the gastrojejunostomy was identified on endoscopy, but not the efferent loop. A CT scan done on day 9 post-operatively revealed an anastomotic leak and a collection of fluid in the left upper quadrant. Mr. S's spleen also appeared infarcted on CT. No lymphadenopathy was seen. A left sided pleural effusion was also present.

The pathology of Mr. S's stomach revealed invasive moderately differentiated adenocarcinoma in the gastric antrum and pyloric regions. As well, there was chronic gastritis and focal intestinal metaplasia in the specimen. *H. pylori* was absent.

There were two lesser omental lymph nodes sampled, and one of these positive for metastatic adenocarcinoma. Five greater omental lymph nodes were negative for malignancy.

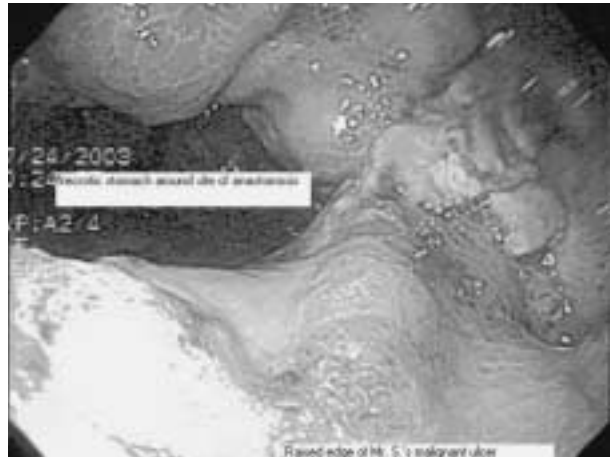


Figure 3. Mr. S.'s malignant gastric ulcer on endoscopy. The black, necrotic area of the stomach is around the anastomosis site. The raised edges at the bottom of the photo are remaining ulcer. These edges were biopsied and adenocarcinoma was found on pathology.

How is Gastric Carcinoma Classified?

Table 2. Staging of Gastric Cancer

Stage IA	tumor invades lamina propria or submucosa (T1) without nodes
Stage IB	T1 tumor with metastasis in 1 to 6 lymph nodes (N1) or T2 N0 (invades muscularis propria or subserosa (T2))
Stage II	T1 tumor with metastasis in 7 to 15 lymph nodes (N2) or T2N1 or T3N0 (penetrates serosa (T3))
Stage IIIA	T2 tumor with N2 nodes or T3 tumor with N1 nodes or T4 tumor (adjacent structures)
Stage IIIB	T3 tumor with N2 nodes
Stage IV	T1-3 tumor with N3 or T4 tumor N1-3 or any T, any N M1 (distant metastasis)

Printed with permission of the American Joint Committee on Cancer (AJCC), Chicago, Illinois. The original source for this material is the AJCC Cancer Staging Manual, Sixth Edition (2002) published by Springer-Verlag New York, Inc.

As was the case for Mr. S, most patients with gastric carcinomas have tumors in the distal stomach (body and antrum). However, the incidence of proximal gastric malignancies is increasing. This appears to be correlated with an increase in the incidence of Barrett's esophagus.⁶ The gold standard for diagnosing gastric malignancies is endoscopy, specifically when ulcerated lesions can be viewed and biopsied (Figure 3). Most gastric malignancies are adenocarcinomas. Advanced carcinomas, such as the one found in Mr. S, are the most common malignancy (35%) where a large tumor is found partly within and partly outside the stomach. Gastric adenocarcinomas can also be classified in terms of differentiation of cells; usually, the rate and extent of spread correlates with lack of differentiation.¹ In Mr. S, his tumor cells were of the moderately differentiated,

Table 3. Risk Factors for Development of Gastric Cancer

Precursor conditions for gastric cancer	Genetic and environmental factors
Chronic atrophic gastritis and intestinal metaplasia	Family history of gastric cancer
Pernicious anemia	Blood type A
Partial gastrectomy for benign disease	Hereditary nonpolyposis colon cancer syndrome
<i>H. pylori</i> infection	Low socioeconomic class
Gastric adenomatous polyps	Low consumption of fruits and vegetables
Barrett's esophagus	Consumption of salted, smoked or poorly preserved foods
Menetrier's disease	Cigarette smoking

Adapted with permission from the New England Journal of Medicine, Volume 333(1), Jul 6, 1995:32-41.

intestinal glandular type, carrying with it a better prognosis than the diffuse-cell type. Three quarters of patients with gastric adenocarcinoma have metastases on initial presentation. The staging of gastric cancer is outlined in Table 2.

The mean age of diagnosis for gastric cancer is 63, and is twice as common in men as it is in women. In terms of specific precursor conditions to gastric carcinoma present in Mr. S, his pathology report showed chronic atrophic gastritis with intestinal metaplasia.⁶ As well, Mr. S had a chronically low vitamin B₁₂ level – potentially indicating a diagnosis of pernicious anemia – which is also a precursor to gastric adenocarcinoma. It is not known whether Mr. S had a Schilling's test as an investigation for pernicious anemia. Other factors that may have predisposed Mr. S to gastric cancer would certainly be his past history of infection with *H. pylori*, as well as a 30-pack-year history of cigarette smoking. Other risk factors and precursor conditions are listed in Table 3.

Although there has been an overall decline in the incidence of gastric cancer, it still remains the second most common cause of cancer-related death in the world.⁶ Unfortunately, patients with gastric cancer typically present once their condition has already metastasized. In terms of cure, the only option is resection. About 85% of patients are operable for this condition, and 50% of tumors can be resected. Surgically, the tumor should be removed with uninvolved margins, as well as an excision of regional lymph nodes.¹ A Billroth I (partial gastrectomy and gastroduodenotomy) or II (partial gastrectomy and gastrojejunostomy) procedure is often performed (Figure 2). Gastric carcinoma is relatively resistant to radiotherapy and no survival benefit to radiotherapy alone after resection has been demonstrated.⁶ Adjunctive chemotherapy is also used in gastric cancer alone or to augment radiotherapy. Although it has been shown to reduce tumor mass in gastric cancer, as well as eradicating micrometastases along with radiotherapy after resection, large randomized trials have consistently shown that adjuvant chemotherapy offers no increased survival benefit over surgical resection of gastric carcinoma.⁶

RESOLUTION

On post-operative day 11, Mr. S was very stable, mobilizing, passing flatus and bowel movements. His left upper quadrant fluid collection was drained percutaneously under radiologic guidance. At the time of writing, Mr. S. remained in hospital six weeks after his admission, and continued stable. He was likely to have a jejunostomy feeding tube placed, as another surgery to repair his anastomosis would be difficult secondary to inflammation and necrotic tissue. Sadly, in patients like Mr. S with Stage 4 disease (T4, N1, M0), the five year survival rate is only in the range of 0-9%.^{1,5} †

ACKNOWLEDGEMENTS

Dr. R. A. Kessaram, General Surgeon, for his role in saving this patient's life.

AUTHOR BIOGRAPHY

Catherine Hanley is a first year general surgery resident at McMaster University, having graduated from McMaster's undergraduate medical program in the spring of 2004. She has a Bachelor of Science degree in Occupational Therapy which she received from the University of Western Ontario in 1991. She had been a practicing pediatric occupational therapist for many years before starting her medical training.

REFERENCES

- Way, Lawrence W. and Doherty, Gerard M. (2003). Current Surgical Diagnosis and Treatment, 11th ed McGraw-Hill Companies, Inc., USA.
- Suerbaum, S. and Michetti, P. (2002). "Medical Progress: Helicobacter pylori infection." *New England Journal of Medicine*. 347: 1175-1186.
- Lawrence, P. (2000). Essentials of General Surgery, 3rd ed. Lippincott Williams & Wilkins, Philadelphia.
- Layke, D.O. and Lopez, P.P. (2004). "Gastric Cancer: Diagnosis and Treatment Options." *American Family Physician*. 69(5): 1133-1140.
- Schroy, PC. (2003). "Clinical Features and Diagnosis of Gastric Cancer." In: *UpToDate*, Rose, BD (Ed), UpToDate, Inc., Wellesley, MA.
- Fuchs. (1995). "Medical Progress: Gastric Carcinoma." *New England Journal of Medicine*. 333: 32-41.